

Research Article



Nanotechnology in Wound Healing; Semisolid Dosage Forms Containing Curcumin-Ampicillin Solid Lipid Nanoparticles, *In Vitro*, *Ex Vivo* and *In Vivo* Characteristics

Solmaz Ghaffari^{1,2*}, Faezeh Alihosseini¹, Seyed Mahdi Rezayat Sorkhabadi^{1,3,4}, Sepideh Arbabi Bidgoli^{1,5}, Seyyedeh Elaheh Mousavi⁶, Setareh Haghighat⁷, Ahoo Afshar Nasab¹, Nooshin Kianvash²

¹Pharmaceutical Sciences Research Center, Pharmaceutical Sciences Branch, Islamic Azad University (IAUPS), Tehran, Iran.

²Young Researchers and Elite Club, Pharmaceutical Sciences Branch, Islamic Azad University (IAUPS), Tehran, Iran.

³Department of Medical Nanotechnology, School of Advanced Sciences and Technology in Medicine, Tehran University of Medical Sciences (TUMS), Tehran, Iran.

⁴Department of Pharmacology and Toxicology, Pharmaceutical Sciences Branch, Islamic Azad University, (IAUPS), Tehran, Iran.

⁵Department of Toxicology, Pharmaceutical Sciences Branch, Islamic Azad University (IAUPS), Tehran, Iran.

⁶Department of Pharmacology, School of Medicine, Tehran University of Medical Sciences, Tehran, Iran.

⁷Department of Microbiology, Faculty of Advanced Sciences and Technology, Pharmaceutical Sciences Branch, Islamic Azad University (IAUPS), Tehran, Iran.

Article info

Article History:

Received: 17 May 2018

Revised: 21 July 2018

Accepted: 9 August 2018

ePublished: 29 August 2018

Keywords:

- Wound healing
- Solid Lipid Nanoparticles
- *In vivo*
- Semi solids

Abstract

Purpose: Wound healing is a natural biologic process, but the duration of it may take too long. Trying to shorten this process is one of the challenges for scientists. Many technologies including nanotechnology were applied to achieve this goal. In this study semi solid formulations containing curcumin and ampicillin solid lipid nanoparticles (SLNs) were prepared and evaluated as new burn wound healing dosage forms.

Methods: Curcumin as an anti-inflammatory and anti-bacterial agent and ampicillin as an antibiotic were used in formulations. *In vitro* and *in vivo* evaluations were carried out. Particle size, loading efficiency, release profile, morphology and anti-bacterial efficacy of desired nanoparticles were evaluated. *Ex vivo* and *in vivo* studies were done to evaluate toxicity and efficacy of the formulations.

Results: Desired nanoparticles were spherical in shape and particle size of the SLNs were in range of 112-121 nm. For increasing stability of particles, they were freeze dried using cryoprotectant. After lyophilization, no significant size enlargement was seen. Results showed that both ointment and gel preparations have reasonable anti-bacterial effects, both of them cause increasing in the rate of wound healing in comparison with placebos and control groups and none of the formulations showed acute toxicity.

Conclusion: It seems that using nanotechnology could shorten wound healing process to reduce treatment costs and increase compliance of patients.

Introduction

Wounds may happen frequently in anyone's life. Wound healing is a biological process which involves four main phases including: hemostasis, inflammation, proliferation and maturation.^{1,2} Nanotechnology researchers focus on wound healing as well as many other medical complains. Probable effectiveness of nano silver (Ag), gold (Au), copper (Cu), zinc (Zn) as well as antibiotic containing nanoparticles were reported previously for wound healing.³ Most of mentioned nanoparticles show antibacterial activity and help to reduce wound healing duration. Researchers demonstrated that nanofibers can be effective in skin regeneration as their structures are similar to the extracellular matrix.⁴ Numerous innovative nanoscale products have emerged for wound healing that

are currently under clinical investigations.⁵ Nash and Hugh demonstrated that topical ampicillin could help to reduce the incidence and frequency of infections after surgery of the large intestine (colon). Researchers did not report significant side effects after using topical ampicillin.⁶ Based on our knowledge there is no publication in which curcumin and ampicillin nanoparticles be used together in a unique semi solid formulation for burn wound healing. In the present research we tried to evaluate the probable benefit of topical administration of nano curcumin-ampicillin in wound healing. Preparation of suitable semi solid dosage forms which could be used for *in vivo* studies was the main goal of this project. After achieving the optimum formulations, *in vitro*, *ex vivo* and *in vivo* studies were carried out.

*Corresponding Author: Solmaz Ghaffari, Tel: +98 21 22640053, Fax: +98 21 55543301, Email: ghaffari.s@iaups.ac.ir

© 2018 The Author(s). This is an Open Access article distributed under the terms of the Creative Commons Attribution (CC BY), which permits unrestricted use, distribution, and reproduction in any medium, as long as the original authors and source are cited. No permission is required from the authors or the publishers.

Materials and Methods

Material

Tween 80, ethanol, acetone and mannitol were purchased from Merck, Germany. Curcumin was prepared by Sami Lab, India. Ampicillin was prepared by Kosar Pharmaceutical Co, Iran.

Preparation of SLNs

Curcumin and ampicillin solid lipid nanoparticles (SLNs) were prepared using high pressure homogenization method which was described by Varshosaz et al.⁷ In brief active substances were dissolved/dispersed in water and tween 80 was added. Hot oily phase was prepared separately, it contains cholesterol and ethanol/acetone (in volume ratio of 3/1). Then oily phase was added to the watery phase under homogenization (13500 rpm). SLNs were prepared during homogenization and cooling of the mixture to the room temperature. Prepared SLNs were lyophilized using 5% mannitol as cryoprotectant.⁸ Particle size, zeta potential, morphology, drug loading efficacy and antibacterial activities as well as drug release profile (before and after lyophilization) were investigated.

Preparation of semisolid formulations

Among different semi solid dosage forms, ointments and emulgels were the selected dosage forms for preparation and evaluation in this study.

Ointment preparation

Petroleum (4.7 g) and Eucerin (4.3 g) were melted and cacao butter and olive oil, 0.2 and 0.6 g respectively, were added. 0.6 g glycerin was added to the mixture. The mixture cooled down to room temperature and then 255 mg lyophilized curcumin and 192 mg lyophilized ampicillin SLNs were added. Net weight of curcumin and ampicillin in the applied SLNs were 70 and 18 mg respectively. The final mixture was blend to achieve a soft and well homogenized ointment.

Emulgel preparation

0.8 g carbopol (971) added to 10 mL distilled water. Then olive oil (2 g) and glycerin (3 g) were added and mixed completely, after achieving a well homogenized gel, 255 and 192 mg of freeze dried curcumin and ampicillin SLNs were added.

Antimicrobial evaluation

Muller-Hinton agar (MHA) plates method was used for *in vitro* antimicrobial testing as recommended by the Clinical and Laboratory Standards Institute. Bacterial strains were sub cultured from frozen stocks. Each bacteria strain (*Escherichia coli*, *Staphylococcus aureus*, and *Pseudomonas aeruginosa*) were inoculated into MHA plates to form a bacterial lawn. Then swabs were wet in different formulations and were stretched on the central inoculated MHA agar. The inoculated plates were

incubated at 37°C and examined after 18-24 hours. The zones of inhibition that obtained were measured and the results were compared. This study was performed in triplicate for each formulation.

Animal studies

Animal housing and maintenance for safety studies

Female rabbits were individually housed in separate quarters in solid bottom cages. Individual animals were identified by color coding, the animal number and group number also appeared on the outside of each cage to preclude mix-up. The animal room environment was controlled (targeted ranges: temperature 22°C to 25°C, relative humidity 20%-30%) and monitored daily. The photo-cycle was 12 hours light and 12 hours dark. All animals were submitted to a general physical examination and all were found healthy and were admitted. Diet and water were offered ad libitum throughout the acclimatization and study periods. The cage cleaning schedule, air filtration and recirculation, health checks and facility maintenance were carried out in accordance with the IAUPS Standard Operating Procedures, and such activities were recorded in the animal room records.

Animal selection/randomization

The test population of animals was selected from newly arrived and the method of randomization was based upon the random selection of numbers generated from a set of numbers without replacement.

Skin irritation and corrosion test

Acute skin irritation and corrosion study of the test article, curcumin and ampicillin SLNs were carried out before starting the topical administration of preparations on the animal burn model to protect animals from probable side effects. The study was conducted according to OECD 404 protocol, Acute Dermal Irritation and Corrosion Test. The test substance was applied in a single dose to the skin of the first rabbit and untreated skin areas of the test animal serve as the control. The degree of irritation/corrosion was read and scored at specified intervals and was further described in order to provide a complete evaluation of the effects. The duration of the study was sufficient to evaluate the reversibility of the effects observed. All rabbits received the test article by dermal application according to the test guideline. Animals were observed individually at least once during the first 4 hours after dosing, periodically during the first 24, 48, 72 hours (with special attention given during the first 4 hours), and daily thereafter, for a total of 14 days, except where they need to be removed from the study and humanely killed for animal welfare reasons or are found dead. All observations were systematically recorded with individual records being maintained for each animal. Body weights were recorded before initiation of the treatment, and daily until the end of the study.

Animal's manipulation for creating skin burn model

Adult male Wistar rats weighing 200–230 g were obtained from Animal house of Experimental Medicine Research Center of Tehran University of Medical Sciences. These animals were housed with ad libitum access to pellet food and water, under standard room temperature ($22\pm 2^\circ\text{C}$) on the 12 hours light/dark cycles. The bedding materials for rats were replaced with new ones every day.

Experimental protocol for generation of burn skin model and burn healing

The animals were anaesthetized with an intraperitoneal injection of ketamine (80 mg/kg) and xylazine HCL (10 mg/kg). The skin of dorsum was shaved and cleaned with 70% ethanol. An experimental skin burn model was induced on rats by the Edraki method.⁹ Second-degree burn wounds on the dorsum of the animals were exposed to ionic cylindrical devices with a surface of 2.5 cm^2 for 10 seconds. The devices were heated in boiling water ($98\pm 1^\circ\text{C}$) at least 20 minutes before application to induce burn injury. Rats were randomly divided into either control or experimental groups. Control group did not receive any treatment. Experimental groups were subdivided into six groups as follows: Group 1 received topical ointment, group 2 received topical gel, group 3 received blank of ointment formulation which contains all ingredients except desired nanoparticles, group 4 received blank of gel formulation which contains all ingredients except desired nanoparticles, groups 5 and 6 received solution of curcumin and ampicillin and normal saline respectively. Each rat treated with equal volume of topical formulation, once daily with regards to the assigned group and continued until 12 hours before sample collection.

In order to collect samples for histopathology examination, the animals were euthanized at 7 and 14 days after inducing burn injury. These samples were preserved in 10% formalin for light microscopic study. Measurement of wounds size was continued until last day.

Histological assessments

Tissue samples of burn wounds for histopathological analysis were immediately fixed in 10% formalin, and then the sections were embedded in paraffin. The section blocks of $5\ \mu\text{m}$ were prepared and stained with hematoxylin and eosin (H&E) for histopathological examination by light microscopy. All skin tissues were examined in a blinded manner by a pathologist. Inflammation, collagen deposition, angiogenesis, granulation tissue formation and epithelialization were graded as 0-3 to each section.¹⁰ The burn wounds surface area, were photographed at the 0th, 5th, 11th, 14th, 18th and 21st days using a digital camera; then, the healing rate was evaluated by comparison of wound area at each control days with the wound area in the first day.¹¹

Results and Discussion

Particle size and morphology evaluation of nanoparticles

Scanning electron microscope (SEM) photographs demonstrated that most of the particles are spherical in shape and after freeze drying non-significant size enlargement was seen. Figure 1a and 1b show SEM photographs of the desired nanoparticles.

Antimicrobial efficacy of formulations

Enhancement of antibacterial efficacy of different active ingredients including curcumin and ampicillin was reported previously.¹²⁻¹⁴ Also previously Varaprasad et al demonstrated the benefit of using curcumin with Ag hydrogel to enhance antibacterial efficacy. Their study results showed that curcumin could enhance antibacterial efficacy of Ag nanoparticles.¹⁵

The “well diffusion test” was carried out using *P. aeruginosa* (ATCC 27853), *S. aureus* (ATTC 25923) and *E. coli* (ATCC 25922). Results demonstrated that the antibacterial efficacy of curcumin-ampicillin SLNs solution is equal with curcumin-ampicillin SLNs in semi solid preparations. So, it seems that the structure and




Figure 1. (a) SEM photo of curcumin solid lipid nanoparticles after freeze-drying (left). (b) Ampicillin solid lipid nanoparticles photograph after freeze-drying (right).

release profile of the active ingredients through SLNs did not change after dosage forms preparation.

Animal studies

In vivo studies were continued for 14 days after administration of dosage forms to the animals. Rate of healing based on wound appearance and diameter was evaluated in comparison with negative and positive controls as well as placebos. Figure 2 (a, b, c, d) shows photos of wound healing after using formulations, placebo and normal saline as blank. Results show that administration of curcumin and ampicillin SLNs cause to decrease healing time of burn wound in comparison with curcumin and ampicillin powders which were dispersed in water. Efficacy of curcumin powder on healing of wounds was studied by scientists, previously. They demonstrated that curcumin can be more effective than silver sulfadiazine.¹⁶ Other researchers tried to overcome poor solubility of curcumin powder by loading that in different vehicles. Hydrogel nanoparticle vehicle showed potential of success in topical administration of curcumin.¹⁷ Curcumin nanoparticles demonstrated efficacy *in vitro* against methicillin-resistant *Staphylococcus aureus* and inhibited growth of this bacteria strain and enhanced wound healing in an *in vivo* burn wound model. These data suggest that curcumin nanoparticles may possess clinical studies as a novel topical antimicrobial and wound healing agent for infected burn wounds.¹⁷ Ahmadi et al demonstrated that using nanotechnology could enhance the rate of burn wound healing. They studied on Ag and tetracycline nanoparticles. Their findings support benefit of the Ag nanoparticles in combination with antibacterial dosage forms which are commonly are using in the market, for the treatment of infectious skin wounds.¹⁸

Pathology studies

Pathology studies confirm that nanotechnology enhances wound healing process. Figure 3(a, b, c, d, e and f) presents the photographs of pathology studies.

As wound healing is a natural process but it is time consuming, healing happened in both control and treated animal groups but the rate of healing was slower in control groups.

In group 1 (Figure 3a) tissue healing with complete and mature re-epithelialization, fibroblast proliferation, and collagen fiber was seen after 14 days. In this group ointment formulation was applied. In group 2 (Figure 3b) complete and mature epithelization was seen. There was a severe fibroplasia (arrow) with high level of collagen fiber. This group was treated by gel formulation.

In group 3 (Figure 3c) incomplete epithelization (arrow) with severe fibrosis and moderate inflammatory cells infiltration was seen. For this group placebo of ointment was applied. In group 4 (Figure 3d) partial epithelization (arrow) was reported by pathologist. There was moderate

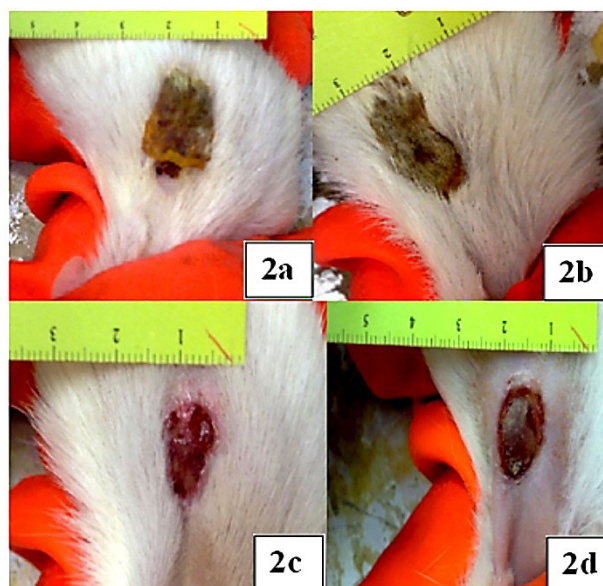


Figure 2. photographs of skin condition after 14 days. a: Group 1, b: Group 2, c: Group 3, d: Group 4.

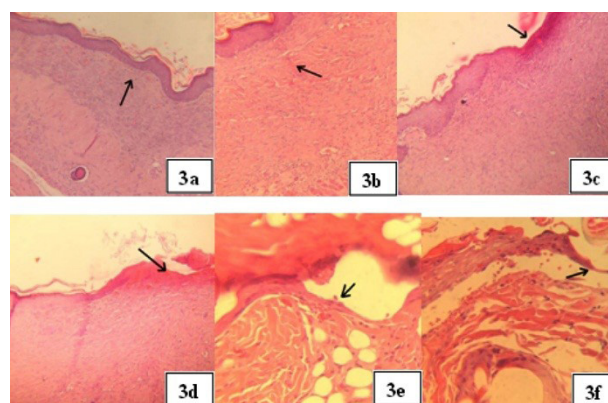


Figure 3. Photographs of pathology studies. a: Group 1 (200×), b: Group 2 (400×), c: Group 3 (200×), d: Group 4 (200×), e: Group 5 (400×), f: Group 6 (400×).

fibrosis in wound area. In this group placebo of gel formulation was applied. In group 5 (Figure 3e) thin epithelization was observed after 14 days. In this group, animals were treated by curcumin-ampicillin solution. In group 6 (Figure 3f) in which normal saline was applied, partial epithelization was observed.

Skin irritation and corrosion test

All animals were examined for signs of erythema and edema, and the responses scored at 60 minutes, and then at 24, 48 and 72 hours after patch removal. For the initial test in one animal, the test site was also examined immediately after the patch had been removed. Dermal reactions were graded and recorded according to the grades in Table 1. If there was damage to skin which could not be identified as irritation or corrosion at 72 hours, observations were continued until day 14 to determine the reversibility of the effects. In addition to the observation of irritation, all local toxic effects, such as defeating of the skin, and any systemic

Table 1. Mean (SD) skin reactions of 3 rabbits after 3 minutes, 1, 4, 24, 48 and 72 hours dermal exposure to proposed solid lipid nanoparticles

Erythema and Eschar Formation	3 min	1 h	4 h	24 h	48 h	72 r	Edema	3 min	1 h	4 h	24 h	48 h	72 r
No erythema	0	0	0	0	0	0	No edema	0	0	0	0	0	0
Very slight erythema (barely perceptible)	0	0	0	1	1	1	Very slight edema	0	0	0	0	0	0
Well defined erythema	0	0	0	0	0	0	Slight edema	0	0	0	0	0	0
Moderate to severe erythema	0	0	0	0	0	0	Moderate oedema	0	0	0	0	0	0
Severe erythema	0	0	0	0	0	0	Severe edema	0	0	0	0	0	0
Skin dryness	0	0	0	0	1	0	Weight of Animals: 3865±108						
Total score: 4	0	0	0	1	2	1							

adverse effects (e.g., effects on clinical signs of toxicity and body weight), were fully described and recorded.

Observations of the first examined rabbit were described in Table 1. The proposed SLNs exposed areas did not show any sign of toxicity after first 4 hours from dermal application. In long term continuous dermal exposure, very slight erythema and dryness were observed but these mild signs of toxicity were recovered to normal appearance after the removal of the patch in case areas. The mean total score was 4 in treated rabbits therefore the product showed very slight irritant effect without any corrosive response in long term (>24 hours) exposure. After the recovery period all animals had normal appearance and hair growth in treated areas. Based on the foregoing results, the SLNs samples did not show any irritant effects even after long term (>72 hours) in treated animals in comparison with control areas in Albino rabbit.

Bodyweight

Control of bodyweight did not show any significant changes in weight of animals.

Conclusion

In this study, semi solid preparations of curcumin and ampicillin SLNs were applied for bun wound healing. Application of both ointment and gel formulations containing SLNs, cause to wound healing in shorter time in comparison with curcumin and ampicillin powders. It seems that using nanotechnology could help to increase rate of wound healing.

Acknowledgments

Research reported in this publication was supported by Elite Researcher Grant Committee under award number [943784] from the National Institutes for Medical Research Development (NIMAD), Tehran, Iran.

Authors would like to appreciate Laboratory of veterinary pathology with managing of Dr Hasti Azarabad for pathology studies. Authors also would like to appreciate kind assistance of Dr. Taraneh Gazori for English polishing of the manuscript.

Ethical Issues

The experimental performed during this study

were approved by Animal Ethics Committee of Tehran University of Medical Sciences.

Conflict of Interest

There is no conflict of interest to declare.

References

- Rex Jeya Rajkumar S, Muthukumar Nadar MSA, Selvakumar PM. Nanotechnology in wound healing-a review. *Glob J Nanomed* 2017;3(1):555605. doi: 10.19080/gjn.2017.03.555605
- Garraud O, Hozzein WN, Badr G. Wound healing: time to look for intelligent, 'natural' immunological approaches? *BMC Immunol* 2017;18(Suppl 1):23. doi: 10.1186/s12865-017-0207-y
- Cortivo R, Vindigni V, Iacobellis L, Abatangelo G, Pinton P, Zavan B. Nanoscale particle therapies for wounds and ulcers. *Nanomedicine (Lond)* 2010;5(4):641-56. doi: 10.2217/nnm.10.32
- Alberti T, Coelho DS, Voytena A, Pitz H, de Pra M, Mazzarino L, et al. Nanotechnology: a promising tool towards wound healing. *Curr Pharm Des* 2017;23(24):3515-28. doi: 10.2174/1381612823666170503152550
- Hamdan S, Pastar I, Drakulich S, Dikici E, Tomic-Canic M, Deo S, et al. Nanotechnology-driven therapeutic interventions in wound healing: potential uses and applications. *ACS Cent Sci* 2017;3(3):163-75. doi: 10.1021/acscentsci.6b00371
- Nash AG, Hugh TB. Topical ampicillin and wound infection in colon surgery. *Br Med J* 1967;1(5538):471-2. doi: 10.1136/bmj.1.5538.471
- Varshosaz J, Ghaffari S, Khoshayand MR, Atyabi F, Azarmi S, Kobarfard F. Development and optimization of solid lipid nanoparticles of amikacin by central composite design. *J Liposome Res* 2010;20(2):97-104. doi: 10.3109/08982100903103904
- Varshosaz J, Ghaffari S, Khoshayand MR, Atyabi F, Dehkordi AJ, Kobarfard F. Optimization of freeze-drying condition of amikacin solid lipid nanoparticles using D-optimal experimental design. *Pharm Dev Technol* 2012;17(2):187-94. doi: 10.3109/10837450.2010.529149
- Edraki M, Akbarzadeh A, Hosseinzadeh M, Tanideh N, Salehi A, Koohi-Hosseinabadi O. Healing effect of sea buckthorn, olive oil, and their mixture on full-thickness burn wounds. *Adv Skin Wound Care* 2014;27(7):317-23. doi: 10.1097/01.ASW.0000451061.85540.f9
- Abramov Y, Golden B, Sullivan M, Botros SM, Miller JJ,

- Alshahrour A, et al. Histologic characterization of vaginal vs. abdominal surgical wound healing in a rabbit model. *Wound Repair Regen* 2007;15(1):80-6. doi: 10.1111/j.1524-475X.2006.00188.x
11. Verma J, Kanoujia J, Parashar P, Tripathi CB, Saraf SA. Wound healing applications of sericin/chitosan-capped silver nanoparticles incorporated hydrogel. *Drug Deliv Transl Res* 2017;7(1):77-88. doi: 10.1007/s13346-016-0322-y
 12. Alihosseini F, Ghaffari S, Dabirsiaghi AR, Haghghat S. Preparation and evaluation of ampicillin solid lipid nanoparticles. *World J Pharm Sci* 2014;2(9):914-20.
 13. Jourghanian P, Ghaffari S, Ardjmand M, Haghghat S, Mohammadnejad M. Sustained release curcumin loaded solid lipid nanoparticles. *Adv Pharm Bull* 2016;6(1):17-21. doi: 10.15171/apb.2016.004
 14. Alihosseini F, Azarmi S, Ghaffari S, Haghghat S, Rezayat Sorkhabadi SM. Synergic antibacterial effect of curcumin with ampicillin; free drug solutions in comparison with SLN dispersions. *Adv Pharm Bull* 2016;6(3):461-5. doi: 10.15171/apb.2016.060
 15. Varaprasad K, Mohan YM, Vimala K, Mohana Raju K. Synthesis and characterization of hydrogel-silver nanoparticle-curcumin composites for wound dressing and antibacterial application. *J Appl Polym Sci* 2011;121(2):784-96. doi: 10.1002/app.33508
 16. Mehrabani D, Farjam M, Geramizadeh B, Tanideh N, Amini M, Panjehshahin MR. The healing effect of curcumin on burn wounds in rat. *World J Plast Surg* 2015;4(1):29-35.
 17. Krausz AE, Adler BL, Cabral V, Navati M, Doerner J, Charafeddine RA, et al. Curcumin-encapsulated nanoparticles as innovative antimicrobial and wound healing agent. *Nanomedicine* 2015;11(1):195-206. doi: 10.1016/j.nano.2014.09.004
 18. Ahmadi M, Adibhesami M. The effect of silver nanoparticles on wounds contaminated with *Pseudomonas aeruginosa* in mice: an experimental study. *Iran J Pharm Res* 2017;16(2):661-9.